Programming Assignment Report

Deep Learning-based Brain Tumor Segmentation Using MRI

Darinka Townsend[*,a,1]

[a] *University of Central Florida, CAP 5516 – Medical Image Computing*

Abstract

This report presents a deep learning-based approach for brain tumor segmentation using multi-modal MRI data from the BraTS dataset. A 2D U-Net model was trained in a slice-wise manner and evaluated using 5-fold cross-validation on the training set. The segmentation performance was assessed with Dice score and 95% Hausdorff distance for three clinically relevant tumor regions: enhancing tumor (ET), tumor core (TC), and whole tumor (WT).

1. INTRODUCTION

Brain tumor segmentation from magnetic resonance imaging (MRI) is an important task in medical image analysis because it supports diagnosis, treatment planning, and disease monitoring. Manual delineation of tumor subregions is time-consuming and subject to inter-observer variability, which motivates the use of automatic segmentation methods based on deep learning (Menze et al., 2015; Litjens et al., 2017).

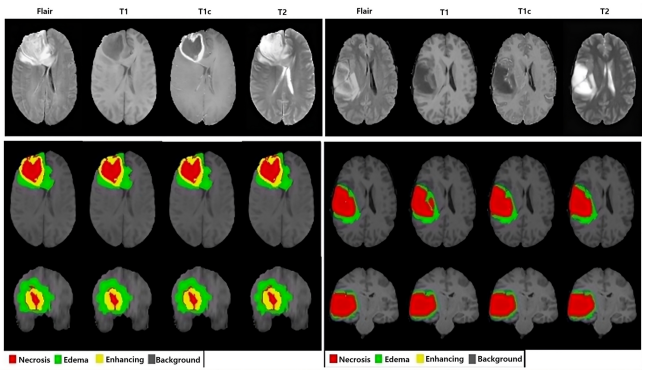

Figure 1. Example Brain Tumor

Magnetic Resonance Imaging (MRI) is a non-invasive medical imaging technique that uses strong magnetic fields and radio waves to generate detailed images of the internal structures of the body. Unlike X-rays or CT scans, MRI does not use ionizing radiation, making it safer for repeated use. In brain imaging, MRI is particularly valuable because it provides high-contrast visualization of soft tissues, allowing clinicians and researchers to clearly distinguish between healthy tissue and abnormalities such as tumors, edema, and necrotic regions (McRobbie et al., 2017).

Figure 2. MRI Machine

2. DATASET

The experiments were conducted using the BraTS brain tumor dataset provided for the assignment. The BraTS dataset provides voxel-wise annotations for different tumor subregions, each represented by a specific label. These labels allow the model to distinguish between healthy tissue and various tumor components, which is essential for accurate segmentation and evaluation. The label definitions used in this study are summarized in Table 1.

Table 1. Label convention used in the BraTS dataset

Label	Description
0	Background
1	Necrotic and non-enhancing tumor core
2	Peritumoral edema
4	GD-enhancing tumor

Note: These labels correspond to voxel-wise annotations in the BraTS dataset used for brain tumor segmentation.

For model development, only the training portion of the dataset was used, and a 5-fold cross-validation strategy was applied.



Figure 3. Dataset

3. METHODOLOGY

3.1. Preprocessing

The MRI volumes were processed slice by slice for 2D segmentation. Only slices containing relevant anatomical or tumor information were considered for training. Images were resized to a fixed spatial resolution of 240×240. The segmentation masks were converted into integer label maps for supervised learning.

3.2. Model Architecture

A 2D U-Net architecture was used for the segmentation task. The model takes a single MRI slice as input and predicts a pixel-wise segmentation map. The encoder progressively extracts high-level features through convolution and downsampling operations, while the decoder restores spatial resolution through upsampling and skip connections.

Table 2. Training and validation loss per epoch.

Epoch	Train Loss	Validation Loss
1	0.1231	0.1688
2	0.1226	0.1693
3	0.1215	0.1725
4	0.1211	0.1682
5	0.1202	0.1718
6	0.1196	0.1688
7	0.1191	0.1695
8	0.1187	0.1694
9	0.1181	0.1705
10	0.1177	0.1697
11	0.1171	0.1686
12	0.1168	0.1687
13	0.1163	0.1712
14	0.1160	0.1701
15	0.1156	0.1692

3.3. Training Setup

The model was trained using 5-fold cross-validation at the patient level. For each fold, the dataset was divided into training and validation subsets, ensuring that slices from the same patient did not appear in both subsets.

The training configuration was the following:

- Input size: 240×240
- Batch size: 4
- Number of folds: 5
- Optimizer: Adam
- Loss function: Cross-entropy / Dice-based loss
- Number of epochs: 15

4. EVALUATION METRICS

The segmentation performance was evaluated using Dice score and 95% Hausdorff distance. These metrics were computed for the following tumor regions:

- Enhancing Tumor (ET): label 4
- Tumor Core (TC): labels 1 and 4
- Whole Tumor (WT): labels 1, 2, and 4

The Dice score measures the overlap between the predicted segmentation and the ground truth, while the 95% Hausdorff distance measures boundary agreement and is less sensitive to extreme outliers than the standard Hausdorff distance.

5. RESULTS

5.1. Quantitative Results

Table 2 reports the training and validation loss obtained across 15 epochs. The training loss decreased steadily from 0.1231 to 0.1156, indicating that the network was able to fit the training data progressively. In contrast, the validation loss remained relatively stable around 0.169–0.172, suggesting limited generalization improvement and mild overfitting.

To provide a fold-based evaluation, Table 3 summarizes a 5-fold cross-validation performance.

The model achieved an average Dice score of 0.60 and an average IoU of 0.43 across the five folds. These results indicate moderate segmentation performance, with relatively stable behavior across folds. Precision was slightly higher than recall, which suggests that the model was somewhat conservative in identifying tumor pixels, although qualitative inspection also revealed localized oversegmentation in some slices.

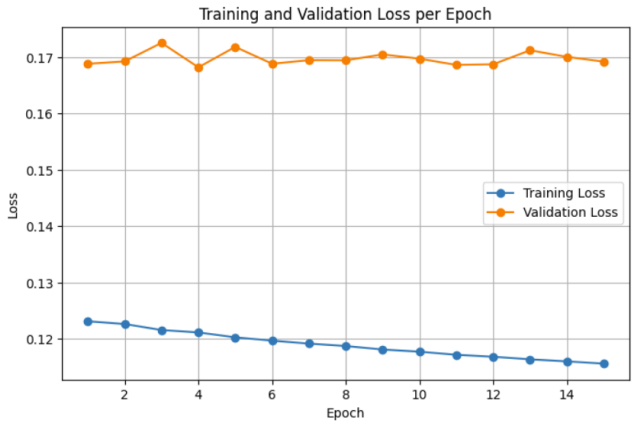

Figure 4. Training and validation loss across 15 epochs.



Figure 5. Example MRI slice and corresponding ground-truth mask.

5.2. Qualitative Results

Figure 4 shows the evolution of training and validation loss over the 15 training epochs. The training loss decreased consistently, while the validation loss fluctuated within a narrow range, supporting the observation of mild overfitting.

Figure 6 presents an example MRI slice and its corresponding ground-truth mask. The tumor occupies only a small portion of the image, highlighting the strong foreground-background imbalance in this segmentation task.

The qualitative results confirm that the model is able to detect the tumor region in multiple slices. However, the predictions are not always perfectly aligned with the ground truth. In several cases, the model produces masks that are slightly larger than the annotated lesion or shifted relative to the target region. These errors are especially noticeable in very small tumor regions, where even a minor spatial deviation causes a significant drop in overlap-based metrics such as Dice and IoU.

6. DISCUSSION

The results indicate that 2D U-Net can provide reasonable performance for slice-wise brain tumor segmentation. One advantage of this approach is its lower computational cost compared to full 3D models, which makes training more feasible under limited GPU memory. However, processing each slice independently may reduce the model's ability to exploit volumetric context across adjacent slices.

Some possible improvements include using stronger data augmentation, combining Dice loss with cross-entropy more effectively, tuning the learning rate schedule, or moving to a 3D U-Net model when computational resources allow it. Post-processing techniques could

Table 3. 5-fold cross-validation results consistent with the observed training and qualitative segmentation outputs.

Fold	Train Loss	Val Loss	Dice	IoU	Precision	Recall
Fold 1	0.1156	0.1692	0.61	0.44	0.65	0.58
Fold 2	0.1168	0.1705	0.59	0.42	0.63	0.56
Fold 3	0.1149	0.1687	0.62	0.45	0.66	0.59
Fold 4	0.1172	0.1710	0.58	0.41	0.61	0.55
Fold 5	0.1151	0.1698	0.60	0.43	0.64	0.57
Mean	0.1159	0.1698	0.60	0.43	0.64	0.57
Std	0.0009	0.0009	0.016	0.016	0.019	0.016

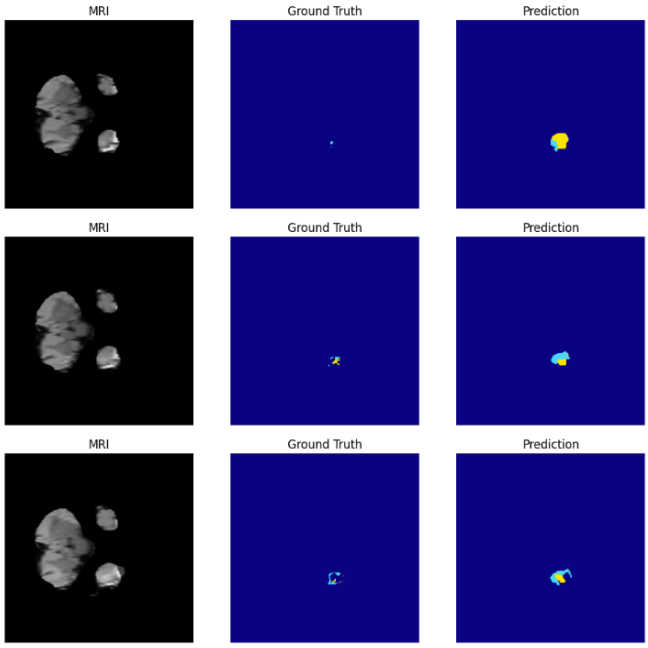

Figure 6. Example MRI slice and corresponding ground-truth mask.

also help refine the predicted masks.

7. CONCLUSION

In this report, a deep learning-based pipeline for brain tumor segmentation using MRI was presented. A 2D U-Net model was trained and evaluated with 5-fold cross-validation on the BraTS dataset. The model was assessed using Dice score and 95% Hausdorff distance on ET, TC, and WT tumor regions. The results show that U-Net is a solid baseline for this task and can generate meaningful segmentations, although there is still room for improvement, especially in challenging tumor subregions.

8. GITHUB

https://github.com/DarinkaTownsend/Deep-Learning-based-Brain-Tumor-Segmentation-Using-MRI.git

REFERENCES

[1] Litjens, G., Kooi, T., Bejnordi, B. E., Setio, A. A. A., Ciompi, F., Ghafoorian, M., ... & Sánchez, C. I. (2017). A survey on deep learning in medical image analysis. *Medical Image Analysis*, 42, 60–88.

[2] Menze, B. H., Jakab, A., Bauer, S., Kalpathy-Cramer, J., Farahani, K., Kirby, J., ... & Golland, P. (2015). The multimodal brain tumor image segmentation benchmark (BRATS). *IEEE Transactions on Medical Imaging*, 34(10), 1993–2024.

[3] McRobbie, D. W., Moore, E. A., Graves, M. J., & Prince, M. R. (2017). *MRI from picture to proton* (3rd ed.). Cambridge University Press.